

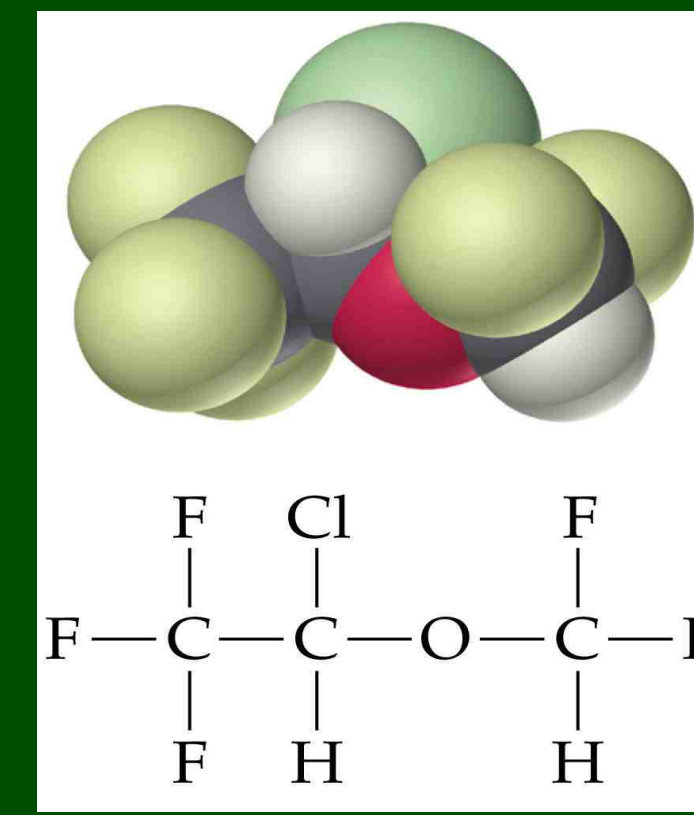
Occupational Asthma and allergy to sevoflurane and isoflurane in Anaesthetic staff

Vellore AD, Drought VJ,

Tunncliffe B, Moore VC ,

Robertson AS² and Burge PS¹

Occupational Lung Disease Unit
Birmingham Heartlands Hospital
Birmingham, United Kingdom



Tel: 0121 424 0734

Email: Sherwood.burge@heartofengland.nhs.uk

Abstract: Isoflurane has caused contact dermatitis in an anaesthetist and dermatitis is common in anaesthetic workers .

We report three cases (anaesthetic assistants or nurses) diagnosed with occupational asthma, work-related angioedema or dermatitis to isoflurane and sevoflurane who underwent specific bronchial provocation testing.

Methods: Increasing exposures to Sevoflurane and isoflurane were delivered on separate days via mask from an air driven anaesthetic machine delivering isoflurane or sevoflurane.

Sequential exposures of 3(0.25%), 5(0.25%) and 7-10 breaths (0.37-0.5%) were given after 10-minute intervals, provided the FEV₁ was within 15% of baseline.

Indirect exposures were with 1 ml of 100% sevoflurane or isoflurane allowed to evaporate in a 6m³ challenge chamber over 1 hour. Post-challenge FEV₁ monitored for 12 hours with a 15% drop over control was considered significant.

Case 1:

Work-related breathlessness, wheeze, chest tightness, rhinitis and eye irritation developed after a latent interval of 4 years of using Isoflurane and Sevoflurane.

Her breathlessness would start within minutes of entering the operating theatres, worsen during her shift and improve after leaving work, then waking her 2-3 times from sleep. Symptoms improved during days away from work and on holidays.

She had had four previous general anaesthetics without incident. Analysis of two hourly peak flow records using the OASYS-2 showed clear evidence of occupational asthma. (OASYS-2 score = 4).

The figure shows a 32% late asthmatic reaction following 15 breaths of isoflurane. Sevoflurane 18 breaths resulted in a 16% FEV₁ fall from baseline at 10 hours (control 11%); Methacholine PD₂₀ developed from >4800 to 2127µg post isoflurane challenge.

She subsequently had an anaphylactic reaction to sevoflurane during general anaesthesia. Occupational asthma resolved following relocation to a psychiatric unit where only intravenous anaesthetics were used (for ECT).

Case 2: She developed wheeze and breathlessness 17 years after first starting work using isoflurane and sevoflurane in operating theatres.

Serial peak flows showed only very small work related changes Oasys score 2.17). Challenge testing to 18 breaths was negative for sevoflurane and equivocal for isoflurane (15% fall at 8 hours).

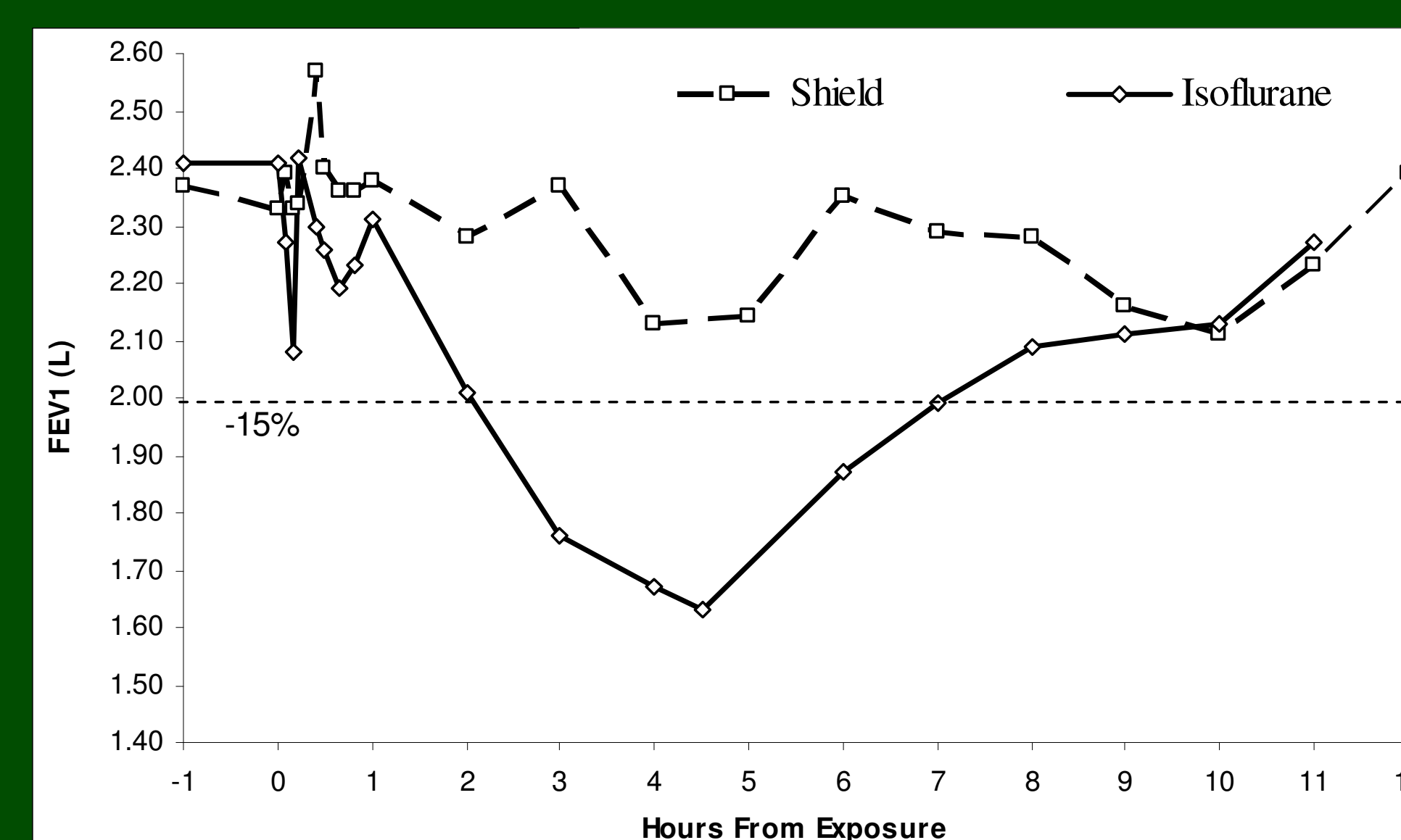
Indirect exposure to sevoflurane resulted in a 14% late asthmatic reaction with a significant change in Methacholine PD₂₀ from 2400 to 900µg. Relocation to the coronary care unit abolished her work-related symptoms.

Case 3: She developed skin rash and facial swelling 3 years after starting theatre work, often accompanied by chest tightness.

There was no change in FEV₁ following any challenge but exposure to Isoflurane was followed by an itchy rash after both direct and indirect methods.

Methacholine reactivity increased from >4800µg to 1745µg. She remains well after to relocation to pre-operative assessment.

FEV₁ fall following Isoflurane inhalation



Conclusion:

All 3 workers came from a department with high number of gas inductions, where adequate scavenging was not achieved during induction and recovery.

Work-related symptoms were abolished after relocation. The subsequent anaphylactic reaction following sevoflurane anaesthesia in the first worker, despite an equivocal challenge, suggests that larger doses during BPT might have been appropriate.

[1] Finch T M et al (2000) Occupational airborne allergic contact dermatitis from isoflurane vapour. *Contact Dermatitis* 42(1):46

[2] Mosconi G, Belotti L et al (1988). Clinico-anamnestic survey in health professionals exposed to volatile anesthetics. *G Ital Med Lav* 10(4-5):165-7.